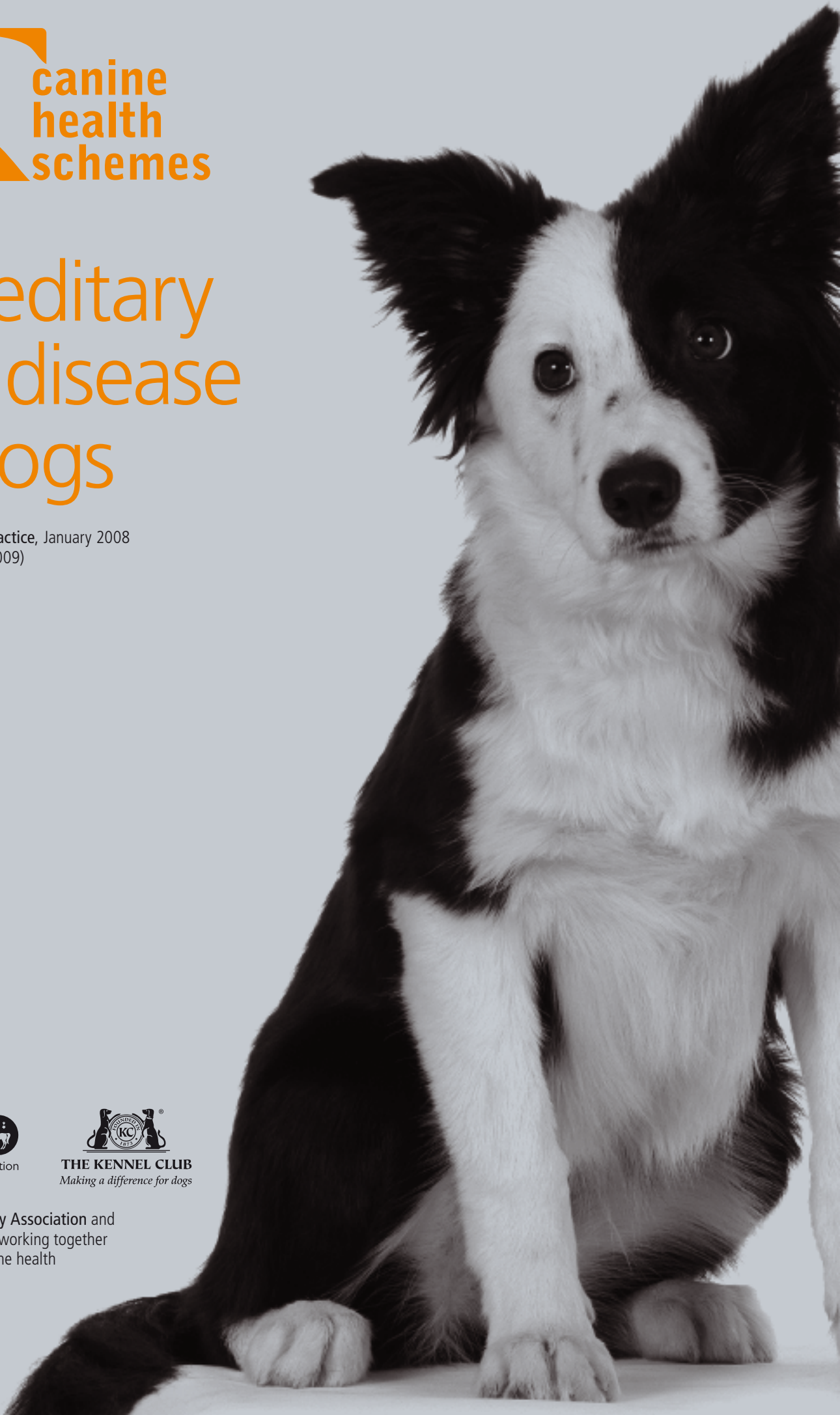




Hereditary eye disease in dogs

Reprinted from *In Practice*, January 2008
(updated February 2009)



The British Veterinary Association and
The Kennel Club — working together
for excellence in canine health



Healthy eyes enhance dogs' quality of life

Hereditary eye disease and the BVA/KC/ISDS Eye Scheme: an update

This article has been written by **Sheila Crispin**, in conjunction with other members of the BVA/KC/ISDS Eye Panel Working Party: **David Gould**, **Stuart Ellis**, **John Mould** and **Peter Renwick**. It is based on an article first published in *In Practice* in June 1995 by **Sheila Crispin**, **Peter Bedford**, **Raymond Long**, **Jeff Yellowley** and **Chris Warren**. A new section on DNA testing for inherited eye diseases is included, written by **Jeff Sampson**.

THE main purpose of the British Veterinary Association/Kennel Club/International Sheep Dog Society (BVA/KC/ISDS) Eye Scheme is to ensure that there is no evidence of hereditary eye disease in dogs that are used for breeding. In order to achieve this aim it is important not only that all dogs that are to be bred from are examined under the scheme, irrespective of whether there are known inherited eye problems within the breed, but that the scheme is kept under active review with regard to inherited eye diseases and breeds that should be included. This article describes conditions that are currently certified (Schedule A) and summarises those that are under investigation (Schedule B). Two categories of inherited eye disease are recognised: congenital (present from birth) and non-congenital (acquired later in life). This simple classification is not entirely satisfactory, because the eyes of puppies are not fully developed at birth and cannot be examined until a puppy is at least four weeks of age. In addition, because the eye is immature at birth, a number of other developmental conditions (eg, geographic retinal dysplasia) may not be apparent at litter screening, so it is more rational to describe inherited congenital conditions as those identifiable during the neonatal stage.

GONIODYSGENESIS/PRIMARY GLAUCOMA

Glaucoma is the term used to describe the effects of a sustained pathological elevation in intraocular fluid pressure. The normal canine intraocular pressure (measured using a Mackay-Marg tonometer) usually lies between 14 and 22 mmHg. Apart from the painful effects of raised intraocular pressure, many of the clinical features of glaucoma are the result of structural ocular damage. In particular, damage to the optic nerve, especially the prelaminar portion, results in partial or complete loss of vision, rendering rapid-onset glaucoma an emergency situation if blindness is to be avoided. Once the process of optic nerve degeneration has begun, the most any effective therapy can achieve is retardation of the loss of sight.

Glaucoma is not a single disease entity, but rather a degenerative process with a number of possible causes. Two broad categories of glaucoma are recognised: primary and secondary. Primary glaucoma is the result of an inherent defect within the aqueous drainage pathway and, in some breeds, the defect is considered to be inherited; the modes of inheritance have not been determined, but clear breed and line predispositions indicate a genetically determined cause. Cases of secondary glaucoma are associated with uveitis, primary lens luxation, trauma and neoplasia.

Classification of conditions

Schedule A conditions

■ CONGENITAL INHERITED CONDITIONS

- Goniodysgenesis/primary glaucoma
- Persistent hyperplastic primary vitreous
- Retinal dysplasia
- Collie eye anomaly
- Congenital hereditary cataract

■ NON-CONGENITAL INHERITED CONDITIONS

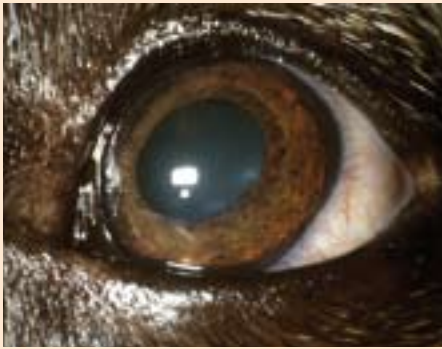
- Hereditary cataract
- Primary lens luxation
- Generalised progressive retinal atrophy
- Retinal pigment epithelial dystrophy (central progressive retinal atrophy).

For some congenital inherited problems, litters of puppies are screened to establish the status of the whole litter. For dogs of any age, individual certificates are issued with respect to the known inherited eye disease(s) for the breed under examination.

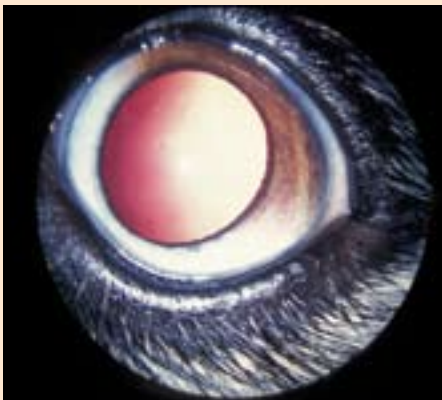
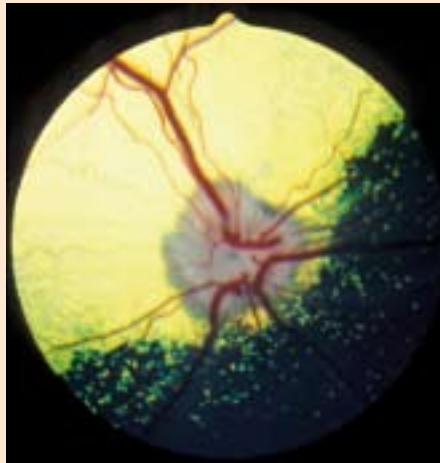
Schedule B conditions

Conditions listed under Schedule B are currently under investigation for evidence of inheritance (see pages 12 to 13).

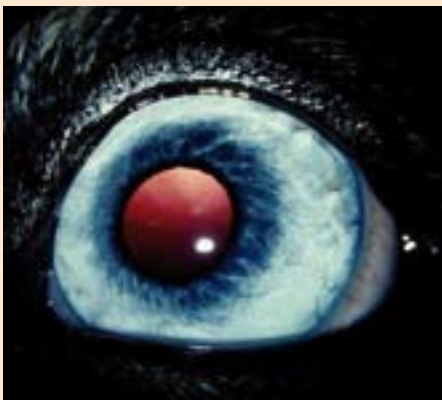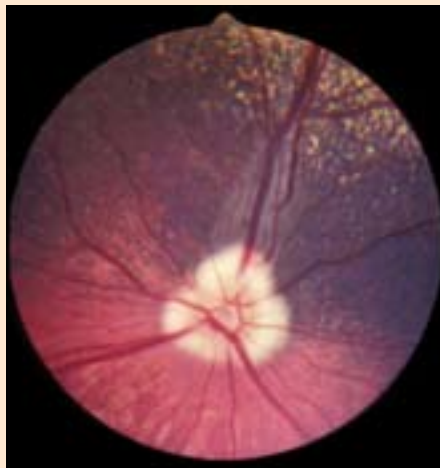
The normal eye



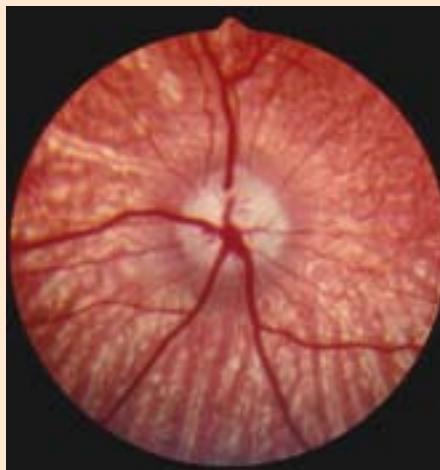
(left) Normal adult eye of a Border Collie with a pigmented iris. (right) Ocular fundus of that eye, showing the tapetal fundus (yellow) dorsally and heavily pigmented non-tapetal fundus ventrally



(left) Normal adult eye of a Crossbred dog with variations of pigmentation (heterochromia) in different sectors of the iris. (right) Ocular fundus of that eye. Note that there is less pigment ventrally, corresponding with the area of reduced pigmentation in the iris



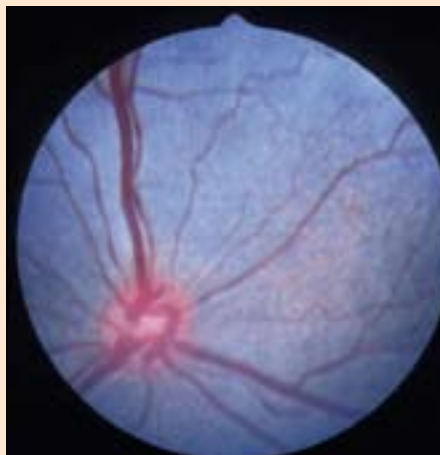
(left) Subalbinotic eye of a normal adult Border Collie. (right) Ocular fundus of that eye. Both retinal and choroidal vessels are visible and there is no tapetum



Picture, Sue Jones



(right) Normal ocular fundus of the eye of the Border Collie puppy pictured on the left. The eyes of newborn puppies are not fully developed at birth and the tapetum has not yet formed in this five-week-old puppy



Although the aetiology is complex, canine primary glaucoma is invariably due to impairment or cessation of aqueous outflow from the anterior chamber of the eye. Aqueous outflow occurs through the iridocorneal angle and, in the dog, the angle is extended posteriorly into the ciliary body as the ciliary cleft. Trabecular meshwork is found within the ciliary cleft and the canine equivalent of the primate's canal of Schlemm – the aqueous plexus – is situated in the scleral tissues that form the outer wall of the cleft. In cases of primary glaucoma, a defect of the iridocorneal angle and the structures associated with the ciliary cleft is responsible for inadequate drainage, leading to an increase in intraocular pressure.

Classification

The classification of primary glaucoma is based on the appearance of the iridocorneal angle as determined by gonioscopy. A suitable lens is placed on the anaesthetised cornea and the magnified view of the angle allows detailed examination of the entrance to the ciliary cleft. Currently, two types of primary glaucoma may be distin-



Gonioscopy lens (Barkan) in place in a Cocker Spaniel. This allows the drainage angle to be examined directly using, for example, a slit lamp or direct ophthalmoscope


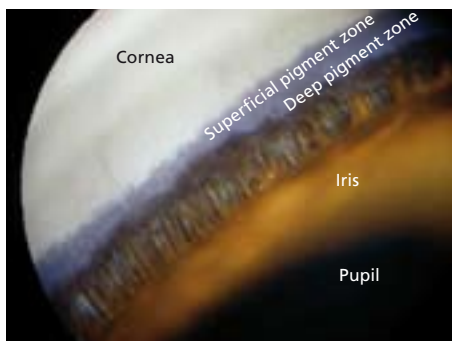
CONGENITAL INHERITED OCULAR DISEASE: GONIODYSGENESIS

Certified – Schedule A	Under investigation – Schedule B
Basset Hound	Dandie Dinmont Terrier
Japanese Shiba Inu	Great Dane
Retriever (Flat Coated)	Hungarian Vizsla
Siberian Husky	Retriever (Golden)
Spaniel (American Cocker)	Welsh Terrier
Spaniel (Cocker)	
Spaniel (English Springer)	
Spaniel (Welsh Springer)	
Spanish Water Dog	

guished: angle-closure glaucoma and open-angle glaucoma. This nomenclature has been ‘borrowed’ from human medicine and, although acceptable, it does not describe the situation completely. When these terms are used to describe primary glaucoma in the dog they denote the appearance of the entrance to the ciliary cleft. Thus, in cases of angle-closure glaucoma, the entrance to the cleft is closed and, in cases of open-angle glaucoma, the entrance to the cleft is open.

■ **ANGLE-CLOSURE GLAUCOMA.** In the normal dog, the ciliary cleft entrance is between 1.5 and 2 mm in width and spanned by a number of iris root processes or fibres, collectively referred to as the pectinate ligament. Dogs that develop primary angle-closure glaucoma demonstrate a congenital predisposition to the condition, in that the entrance to the ciliary cleft is usually much narrower than normal, and both eyes are affected. The pectinate ligament is dysplastic and may be seen as sheets of undifferentiated mesenchymal tissue rather than the normal fibrocellular processes. A narrowed iridocorneal angle with pectinate ligament dysplasia is referred to as goniodysgenesis. Breeds that are currently examined for goniodysgenesis under the UK Eye Scheme are listed in the table above. The age at which glaucoma develops tends to vary with breed but the disease is mostly one of middle age and the presentation is often acute and painful. Gonioscopy can be used as a method of screening to identify those animals that are predisposed before the disease makes its appearance. Affected animals should not be bred from. Routine gonioscopy can be performed at five to six months of age in most breeds.

■ **OPEN-ANGLE GLAUCOMA.** This bilateral chronic disease is the result of a low-grade rise in intraocular pressure. The iridocorneal angle remains open until the final stages of the disease and it has been suggested that the impairment of aqueous outflow is due to a defect within the trabecular meshwork and/or the inner scleral tissues.



(left) Normal drainage angle of a Siberian Husky. The drainage angle is of normal width and is spanned by the pectinate ligament. In this poorly pigmented eye, the white band of the scleral shelf is clearly distinguished. There is great variation in the number, width, pigmentation and distribution of the fibres that comprise the pectinate ligament in different breeds, but the width of the normal drainage angle is not subject to such variation (middle) Normal drainage angle of a Flat Coated Retriever. The width of the drainage angle is normal and the fibres of the pectinate ligament are clearly defined. This eye is more heavily pigmented than the one pictured on the left and the scleral shelf is obscured by pigment (right) Goniodysgenesis in a Flat Coated Retriever. There is extensive pectinate ligament dysplasia and sheets of mesenchymal tissue occlude the majority of the drainage angle. Aqueous drainage is via a limited number of ‘flow holes’ (an example of which is circled). The drainage angle is slightly narrowed and normal pigment obscures the scleral shelf. The eye was normotensive at the time of examination (intraocular pressure of 18 mmHg measured with a Mackay-Marg tonometer), despite the compromised drainage angle. All three images were photographed using a Kowa RC2 Fundus Camera

The disease is silent in onset and, whereas subtly defective vision heralds its appearance in humans, it is globe enlargement and/or partial blindness that first draw attention to affected dogs. Gonioscopy is not applicable as a screening procedure and routine tonometry can present practical difficulties. Fortunately, the disease is of low incidence in the canine population, with the Miniature Poodle and Norwegian Elkhound being the only breeds in the UK in which there is evidence of possible inheritance. This type of glaucoma is not currently included for certification under the Eye Scheme.

Significance

Goniodysgenesis predisposes dogs to a painful and sight-threatening disease. As treatment of glaucoma is often unsatisfactory for a number of reasons – not least the fact that damage that has already occurred cannot be reversed – examination of susceptible breeds under the Eye Scheme is essential in order to avoid breeding from affected dogs.

PERSISTENT HYPERPLASTIC PRIMARY VITREOUS

The embryonic lens is supplied with nutrients by the hyaloid artery (which grows forward from the optic stalk to reach the posterior lens surface at about day 25 of gestation) and the tunica vasculosa lentis (which is formed by day 30 of gestation). Regression of the vascular supply starts at about day 45 of gestation and is complete two to four weeks after birth. Persistence of these vessels and proliferation of associated mesodermal elements of the tunica vasculosa lentis posterioris produce the main lesion of fibrovascular plaque formation on the posterior lens capsule. This plaque appears as a dense white/yellow opacity and multiple pigment foci may also be attached to the posterior lens capsule. Blood vessels may be visible within the plaque and at its periphery. Other features of persistent hyperplastic primary vitreous include persistent capsulopupillary vessels (iridohyaloid vessels), coloboma of the lens, posterior lenticonus, intralenticular and retrolental haemorrhage, secondary cataract, persistence of the hyaloid artery and Bergmeister's papilla (remnant of the glial sheath around hyaloid vessels on the optic nerve head), and retinal dysplasia.

The mode of inheritance is complex, but the genetic data available suggest an autosomal irregular dominant

gene with variable expression. The breeds examined under Schedule A are listed in the table on the right. There are currently no breeds being investigated for this condition under Schedule B.

CONGENITALLY INHERITED OCULAR DISEASE: PERSISTENT HYPERPLASTIC PRIMARY VITREOUS

Certified – Schedule A
Dobermann
Staffordshire Bull Terrier

Significance

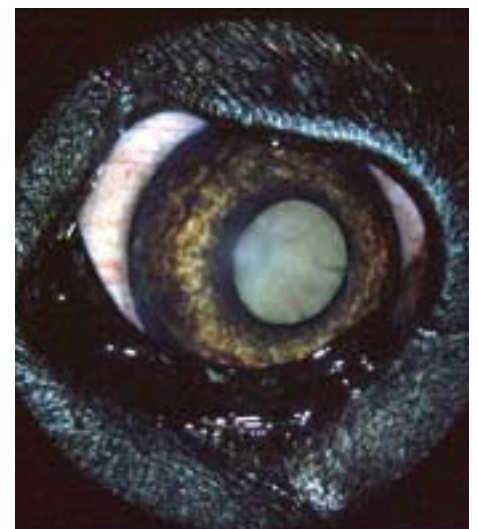
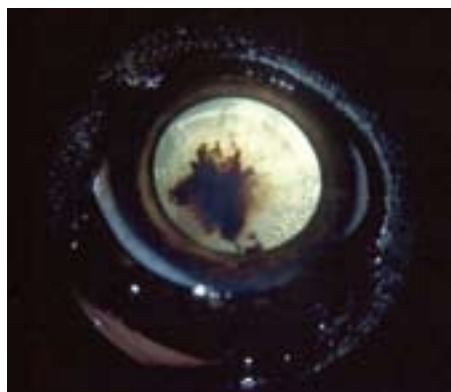Severe lesions cause marked visual loss or blindness. Milder cases of retrolental plaque formation spare the lens periphery and allow adequate vision. Although these milder lesions tend not to cause progressive cataract formation in the Staffordshire Bull Terrier, cataracts in affected Dobermanns often progress to produce severe visual impairment or blindness. The Staffordshire Bull Terrier also suffers less from posterior lens capsule deformities, but has more widespread retinal folds and rosettes than the Dobermann. The condition is not common in either breed in the UK, but the severe form of the disease is a serious congenitally inherited problem, so routine examination is critical. Surgical treatment of those cases with visual problems is fraught with difficulty and there is a high risk of postoperative complications.

RETINAL DYSPLASIA

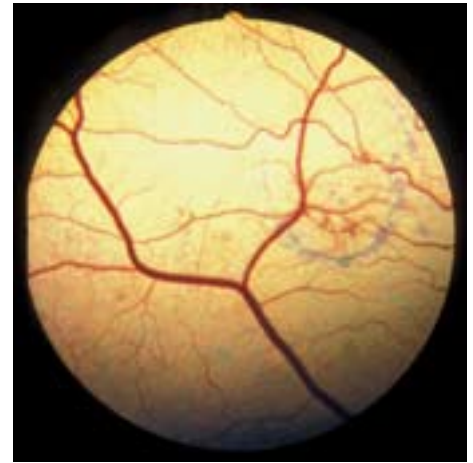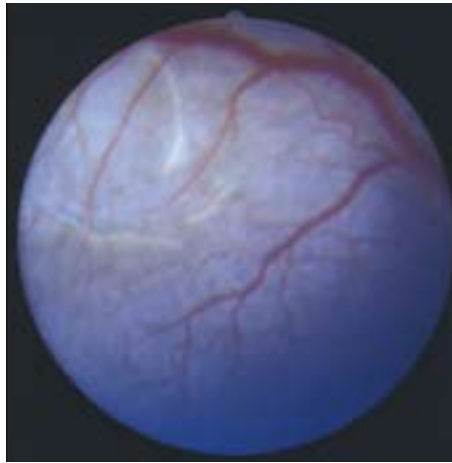
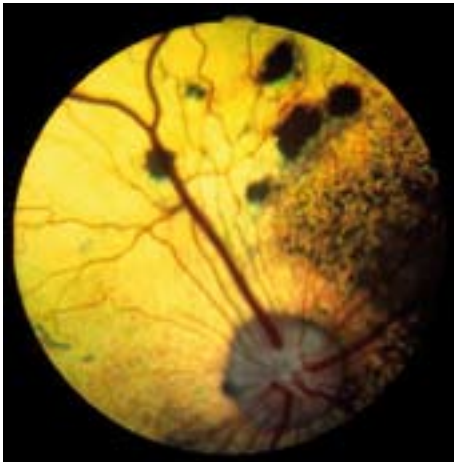
The term retinal dysplasia embraces a number of congenital conditions resulting from disorderly proliferation and atypical differentiation of the retina during embryonic life. In addition to genetically determined hereditary retinal dysplasia, a wide variety of extraneous insults to the developing retina (eg, infection with agents such as canine herpesvirus) may cause acquired, non-inherited, retinal dysplasia. Defective retinal development results in extremely varied clinical and microscopic appearances so that, for example, folds, ridges, rosettes, geographic abnormalities and localised detachments are all possible manifestations of multifocal retinal dysplasia, while total retinal dysplasia is most commonly associated with non-attachment or complete detachment of the retina.

Classification

■ MULTIFOCAL RETINAL DYSPLASIA (MRD). Linear folding of the sensory retina and the formation of rosettes composed of variable numbers of neuronal retinal cells are the histological characteristics of multifocal retinal dysplasia. Typically, the lesions range from vermiform



(left) Persistent hyperplastic primary vitreous in a Dobermann. The white opacity visible through the pupil involves the vitreous and posterior lens capsule. (middle) Persistent hyperplastic primary vitreous. In this dog, the hyaloid vessel has remained patent and there is haemorrhage into the lens. Note the numerous vacuoles within the lens cortex, which are indicative of progressive cataract formation. (right) The same eye as that pictured in the middle some months later after cataract formation



(left) Multifocal retinal dysplasia in an English Springer Spaniel. Some of the larger focal lesions with pigmented centres to the right of the dorsal primary retinal vessels resemble inactive chorioretinopathy, but there are also classical rosettes and vermiform lesions to the left of the vessels. (middle) Geographic retinal dysplasia in a Cavalier King Charles puppy. (right) Geographic retinal dysplasia in an adult Golden Retriever

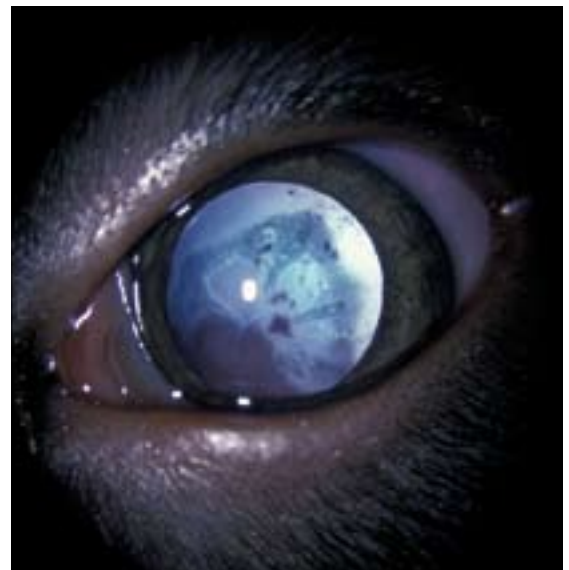grey streaks to multiple focal sites of tapetal hyper-reflectivity, which may or may not be associated with hypertrophy of the retinal pigment epithelium (probably indicative of long-standing detachment). Irregularly shaped (geographic) areas of retinal dysplasia, often with an associated, limited region of retinal detachment, may also be encountered. In most cases, the lesions are most obvious in the tapetal fundus dorsal to the optic disc and close to the dorsal primary retinal vessels.

■ **TOTAL RETINAL DYSPLASIA (TRD).** Somewhat more complex, this form of retinal dysplasia is associated with non-attachment or complete detachment of the retina. Non-attachment may result from apparent failure of contact of the inner (retinal) and outer (retinal pigment epithelial) layers of the optic cup during embryogenesis; other ocular abnormalities, such as microphthalmos and nystagmus, are often present in these cases. In the Bedlington Terrier, most affected dogs have an infundibular retinal detachment. Puppies are blind from birth and may present with leukocoria because the retina is immediately behind the posterior lens capsule. Retinal neovascularisation may result in intraocular haemorrhage. In the Sealyham Terrier, total retinal detachment

is also present and microphthalmos and nystagmus are common findings.

Three forms of retinal dysplasia are recognised as inherited in the Labrador Retriever:

- FORM 1 is associated with complete detachment. The defect seems to result from an inability of the developing retina to match the rapid growth of the choroid and sclera. The resulting detachment leads to degeneration of the neurosensory retina due to ischaemic hypoxia, and such animals are blind. Other ocular defects, such as microphthalmos, nystagmus and cataract, may be present.
- FORM 2, which has not been reported in the UK, is associated with skeletal abnormalities. It is believed to be caused by a single autosomal gene that behaves recessively with respect to the skeleton and exhibits incomplete dominance with respect to the eye. Heterozygotes have normal skeletons and mild multifocal retinal dysplasia, while in homozygotes skeletal changes are present and the eye lesions are mild to severe, with blindness often being obvious by two months of age.
- FORM 3 is classified as multifocal retinal dysplasia and is the most commonly observed form in the UK. It consists of focal lesions of various shapes (eg, round, oval,



(left) Total retinal dysplasia in a Labrador Retriever puppy. (above) Close-up of the eye of this puppy. The retina can be visualised behind the lens

CONGENITAL INHERITED OCULAR DISEASE: RETINAL DYSPLASIA

Certified – Schedule A (TRD)

Bedlington Terrier
Sealyham Terrier

Certified – Schedule A (MRD)

Cavalier King Charles Spaniel
Hungarian Puli
Retriever (Golden)
Rottweiler
Spaniel (American Cocker)
Spaniel (English Springer)

Certified – Schedule A (TRD and MRD)

Retriever (Labrador)

Under investigation – Schedule B (MRD)

Beagle
Collie (Rough)
German Shepherd Dog
Giant Schnauzer
Norwegian Elkhound
Spaniel (Field)
Spaniel (Sussex)

TRD Total retinal dysplasia, MRD Multifocal retinal dysplasia

linear) as well as geographic abnormalities. Geographic retinal dysplasia is often associated with circumscribed flat retinal detachment in young dogs but, typically, reattachment occurs with time. The multifocal third form is not associated with any systemic abnormalities.

Significance

A simple autosomal recessive gene is responsible for retinal dysplasia in most of the breeds studied (with the exception of the skeletal abnormality-associated form in the Labrador Retriever). Diagnosis is complicated by the fact that:

- Not all types of retinal dysplasia are inherited;
- Ophthalmoscopic changes may be more difficult to detect in the developing eye;
- There is evidence that some types (eg, geographic) develop at variable intervals after birth.

While many dogs with multifocal retinal dysplasia will have no obvious visual defect, some are severely visually impaired, as are all dogs affected with total retinal dysplasia. There is, therefore, no question of not examining 'at risk' breeds under the Eye Scheme (see table above).

COLLIE EYE ANOMALY

Collie eye anomaly has a worldwide distribution and ocular lesions of identical ophthalmoscopic appearance have also been described in a number of non-Collie breeds, such as the Lancashire Heeler and Australian Shepherd. The classic lesion is chorioretinal hypoplasia in the lateral or dorsolateral region of the fundus near the optic disc, which is most easily detected in the young puppy, ideally at about five to six weeks of age. There is a range of possible appearances; in some animals, the hypoplasia may be more extensive and it is not uncommon for both eyes in an animal to be dissimilar. The lesion appears as a 'pale patch' due to a localised lack of some, or all, retinal and choroidal pigment and tapetum. The choroidal vessels in the affected region are also abnormal, usually in size, number and disposition. In merle dogs, with little fundic pigment and no tapetum, chorioretinal hypoplasia will be less obvious and, hence, the appearance of the choroidal vessels becomes the important diagnostic feature. In addition to chorioretinal hypoplasia, there may be

papillary and peripapillary colobomas; indeed, colobomatous defects can sometimes be the only abnormality in susceptible breeds. Retinal detachment and intraocular haemorrhage are rare and, therefore, most dogs with Collie eye anomaly show no apparent visual defect.

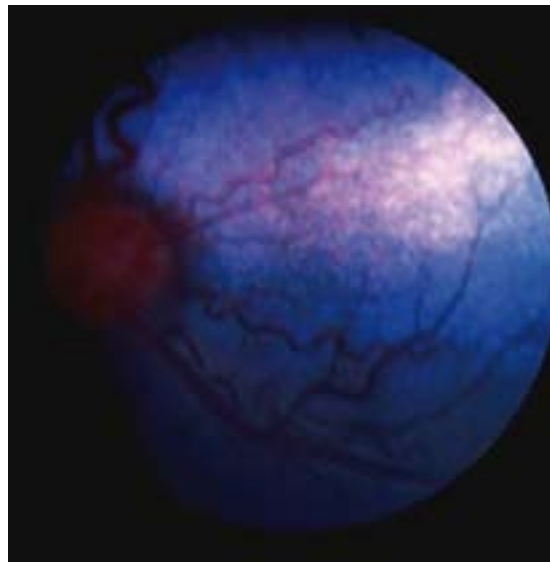
Tortuosity of the retinal vessels and retinal folds (the latter usually manifesting as vermiform streaks) are now not regarded as part of the syndrome, but may relate to the smallness of the eye. There has been no detailed investigation of eye size in relation to Collie eye anomaly.

The chorioretinal hypoplasia that typifies Collie eye anomaly is a simple autosomal recessive trait, but the colobomatous defects seen in a proportion of cases are not inherited in this way. The inappropriate term 'go normal' has been applied to dogs where postnatal development (pigmentation and tapetal development) obscures the chorioretinal hypoplasia, which is the key diagnostic feature, so that adult dogs have a fundus of normal appearance. The phenomenon is common enough to call into question the relevance of examining dogs as adults rather than as puppies. Data on Collie eye anomaly in

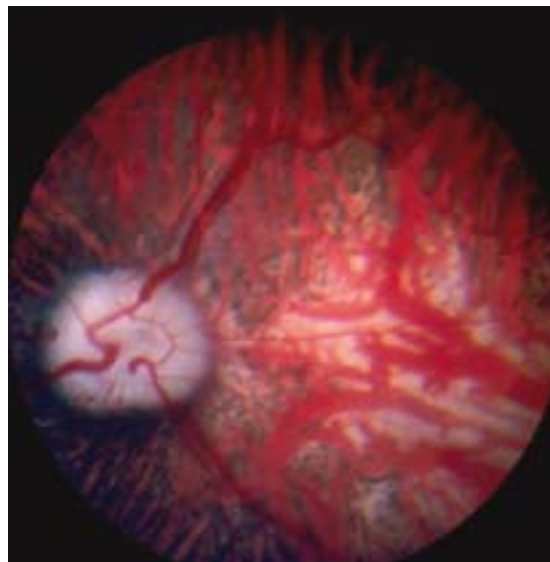
CONGENITAL INHERITED OCULAR DISEASE: COLLIE EYE ANOMALY

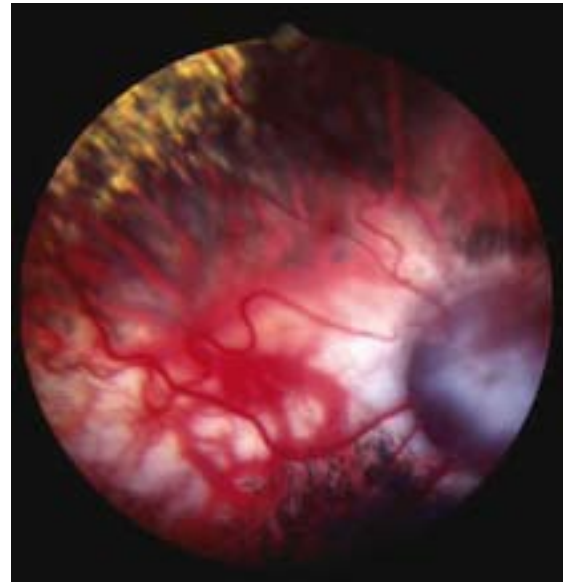
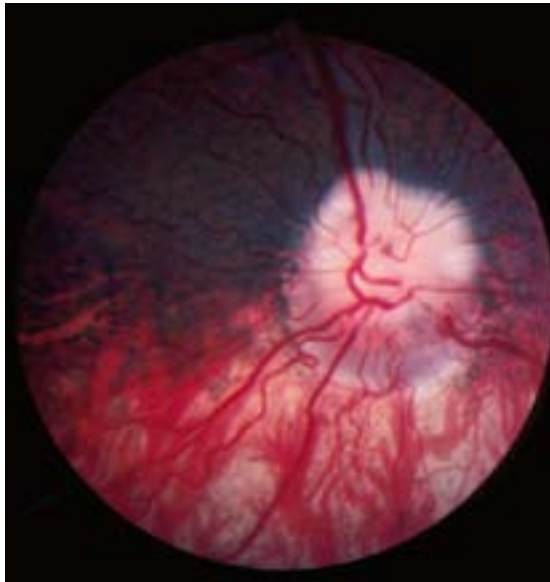Certified – Schedule A

Border Collie
Collie (Rough)
Collie (Smooth)
Lancashire Heeler
Shetland Sheepdog



(above) Collie eye anomaly in a five-week-old Border Collie puppy. A region of chorioretinal hypoplasia (pale patch) is obvious lateral and slightly dorsal to the optic nerve head. (below) Collie eye anomaly in an adult Shetland Sheepdog. Extensive chorioretinal hypoplasia can be seen lateral to the optic nerve head





(left) Collie eye anomaly in an adult Rough Collie. The most striking feature is the peripapillary coloboma ventral to the optic nerve head. (right) Collie eye anomaly in an adult Border Collie. This image is dominated by a large colobomatous defect to the right of the picture and there is also extensive chorioretinal hypoplasia lateral to the coloboma

the Rough Collie in Norway, for example, has indicated that the number of successful diagnoses of the condition in a group of dogs aged more than three months was almost half that for a group of puppies aged seven weeks to three months. Furthermore, when puppies that had been diagnosed as having Collie eye anomaly with mild chorioretinal hypoplasia at between seven weeks and three months of age were re-examined at about one year of age, 68 per cent had a fundus of normal appearance.

Significance

Despite a variety of fundamental issues combining to make Collie eye anomaly a frustrating problem for breeders and veterinary ophthalmologists alike, it is worth emphasising that it is a congenital condition that can be diagnosed as soon as eye examination is possible and that it is diagnosed with greatest accuracy in such young dogs. There is little doubt that, in those breeds examined under the Eye Scheme, litter screening, combined with genetic testing, is the best way of attempting to establish clear lines.

HEREDITARY CATARACT

The canine lens is an asymmetrical, transparent, biconvex sphere, with the more convex aspect positioned posteriorly. The adult lens consists of a central nucleus surrounded by cortical lens fibres and the nucleus itself is divisible into various regions according to age – the oldest, central, portion of the lens is the embryonic nucleus, which is surrounded by the fetal nucleus and outermost the adult nucleus. The whole lens is contained within an acellular capsule (the anterior capsule is thicker than the posterior capsule). A single layer of epithelial cells lies immediately beneath the anterior capsule and it is these cells that form the germinal cell layer that produces new lens fibres throughout life. The epithelial cells migrate peripherally and elongate at the equator (circumference) of the lens. Each fibre extends anteriorly and posteriorly to meet fibres to the front and rear to form the suture lines. The suture lines appear as an upright ‘Y’ anteriorly and an inverted ‘Y’ posteriorly.

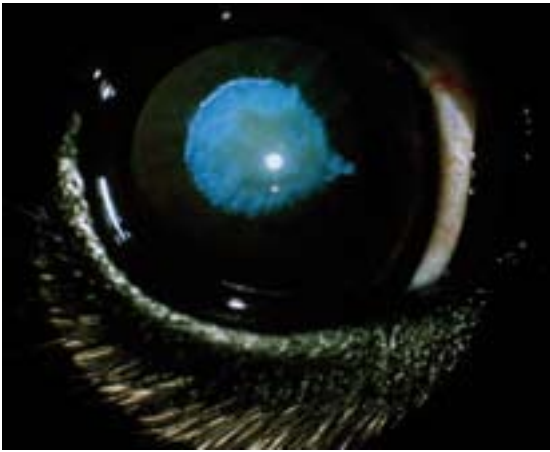
CONGENITAL INHERITED OCULAR DISEASE: CONGENITAL HEREDITARY CATARACT	
Certified – Schedule A	Under investigation – Schedule B
Miniature Schnauzer	Old English Sheepdog Retriever (Golden) West Highland White Terrier

NON-CONGENITAL INHERITED OCULAR DISEASE: HEREDITARY CATARACT	
Certified – Schedule A	Under investigation – Schedule B
Alaskan Malamute Australian Shepherd Belgian Shepherd Dog Boston Terrier Cavalier King Charles Spaniel German Shepherd Dog Giant Schnauzer Irish Red and White Setter Large Munsterlander Leonberger Miniature Schnauzer Norwegian Buhund Old English Sheepdog Poodle (Standard) Retriever (Chesapeake Bay) Retriever (Golden) Retriever (Labrador) Siberian Husky Spaniel (American Cocker) Spaniel (Welsh Springer) Staffordshire Bull Terrier*	Bichon Frise Border Collie Border Terrier French Bulldog Greenland Dog Griffon Bruxellois Lancashire Heeler Spaniel (Field) Staffordshire Bull Terrier* Tibetan Terrier
*More than one type of hereditary cataract can occur within an individual breed	

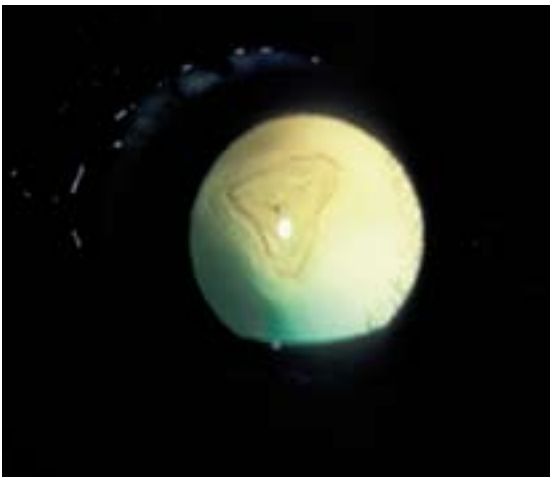
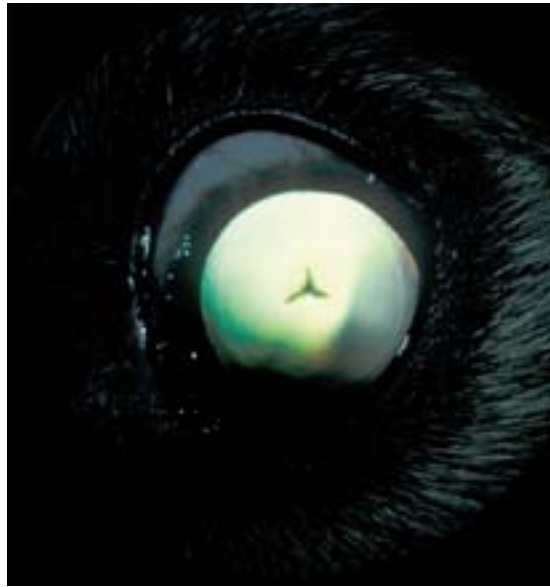A cataract is defined as any opacity of the lens or its capsule. Cataract formation may be:

- CONGENITAL, due to in utero insult;
- TRAUMATIC, as a result of blunt or penetrating injury to the eye;
- METABOLIC, as a consequence of, for example, diabetes mellitus;
- TOXIC, caused by some drugs;
- NUTRITIONAL, produced by inappropriate diets;
- A COMPLICATION OF OTHER PRIMARY OCULAR DISEASES, such as uveitis and neoplasia.

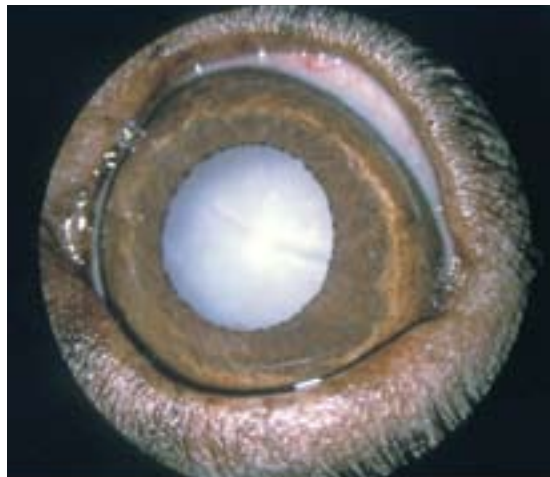A number of cataracts have been demonstrated to be inherited and it is these that the Eye Scheme reviews. The age of onset, appearance and progression of the cataracts that are certified under the Scheme are usually quite spe-



(above) Congenital hereditary cataract in a Miniature Schnauzer. The nuclear portion of the lens is affected and there is a pyramid-shaped extension medially. Picture, Dr Keith Barnett. (right) Hereditary cataract in a Golden Retriever. The characteristic Y-shaped cataract is located in a posterior polar subcapsular position



(left) Hereditary cataract in a Norwegian Buhund. There is an obvious opacity, located posteriorly, involving the posterior pole and posterior suture lines. (right) Total hereditary cataract in a Labrador Retriever



cific within the affected breeds, thus enabling inherited cataracts to be distinguished from cataracts from other causes. At present, the Miniature Schnauzer is the only breed certified under Schedule A for congenital inherited cataract; other Schedule A cataracts are all non-congenital. A number of other congenital and non-congenital cataracts are listed under Schedule B (see pages 12 to 13).

Significance

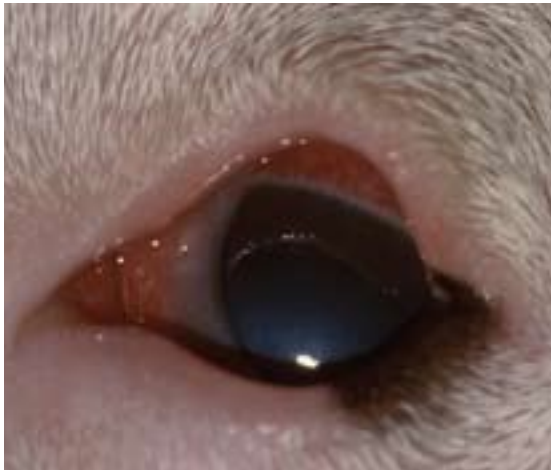
Apart from the undesirable perpetuation of abnormality within breeding lines, a proportion of inherited cataracts progress to produce visual impairment and blindness. The only treatment for cataract is surgical removal and, although modern techniques generally give excellent results, the procedure is a major one for both the patient and the owner.

PRIMARY LENS LUXATION

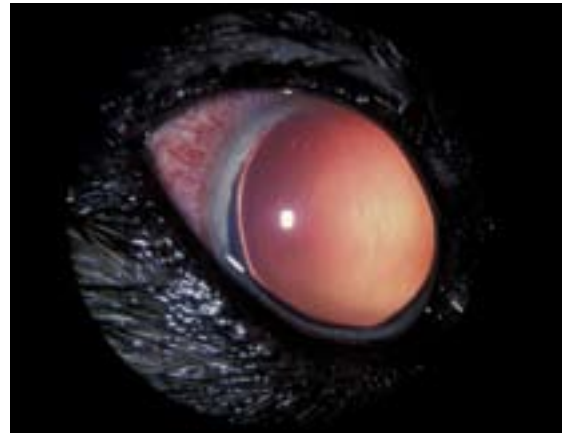
Primary lens luxation is caused by an inherent defect in the zonule that leads to partial or complete dislocation of the lens at around four years of age. Clinical signs are not usually observed before three years of age or later than seven years of age. It is a common cause of secondary glaucoma and, as such, an important disease to recognise

because of the potential for pain and visual loss. Primary lens luxation is recognised as a familial problem in certain terrier breeds, the Tibetan Terrier (which is not a true terrier breed), the Border Collie and the Lancashire Heeler. Although the literature is incomplete, the evidence appears to support a recessive mode of inheritance in most breeds exhibiting primary lens luxation.

The condition is essentially bilateral, but almost invariably presents as a uniocular condition as one eye may be affected weeks or months before the other. It should be noted that lens luxation can also be a secondary complication of primary glaucoma. Observant owners may notice a change in the appearance of the affected eye as the lens moves out of its normal position. When the lens moves anteriorly, secondary glaucoma develops rapidly and pain, blepharospasm, photophobia, lacrimation, an increase in intraocular pressure, together with a widely dilated non-responsive pupil, visual loss and episcleral and conjunctival congestion, are the most obvious clinical features. With posterior lens luxation, secondary glaucoma is less likely, although most lenses move anteriorly at some stage. Careful observation will reveal the displaced lens (the lens equator is usually highlighted by the examination light and there may be a gap or aphakic crescent between the lens equator and the iris). In addition, the iris trembles slightly with head and eye move-



Primary lens luxation in a Miniature Bull Terrier. The changes were acute, and the eye painful and red (episcleral congestion), indicative of glaucoma (the intraocular pressure measured with a Mackay-Marg tonometer was 60 mmHg). The other eye was normotensive (intraocular pressure 22 mmHg). The lens has luxated anteriorly and an area of corneal oedema is apparent as a result of endothelial damage from contact with the lens. The lens equator is highlighted by illumination from a penlight



Lens luxation secondary to primary glaucoma. This eye was painful and red, and the pupil widely dilated. The intraocular pressure measured with a Mackay-Marg tonometer was 68 mmHg. The lens equator is highlighted by illumination from a penlight and an aphakic crescent is apparent laterally. The very fine opacity running vertically down from the dorsal cornea is a rupture of Descemet's membrane (Haab's striae) and indicates that the intraocular pressure had been raised for some time; there was also cupping of the optic nerve head as a further sign of chronicity. The other eye was normotensive (intraocular pressure 16 mmHg)

ment because it has lost the support of the lens.

Significance

Primary lens luxation is an inherited problem that can result in glaucoma and cause persistent pain and blindness without prompt surgical intervention to remove the lens; this is currently also the best documented treatment for lens luxation associated with secondary glaucoma. Affected dogs should not be bred from and at risk breeds that are to be used for breeding should be examined under the Eye Scheme (see table above).

NON-CONGENITAL INHERITED OCULAR DISEASE: PRIMARY LENS LUXATION

Certified – Schedule A
 Border Collie
 Bull Terrier (Miniature)
 Fox Terrier (Smooth)
 Fox Terrier (Wire)
 Lancashire Heeler
 Parson Russell Terrier
 Sealyham Terrier
 Tibetan Terrier

GENERALISED PROGRESSIVE RETINAL ATROPHY

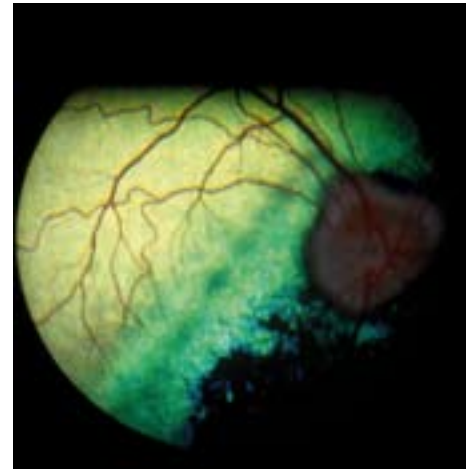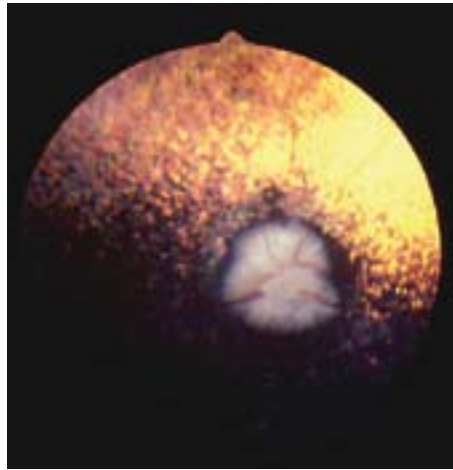
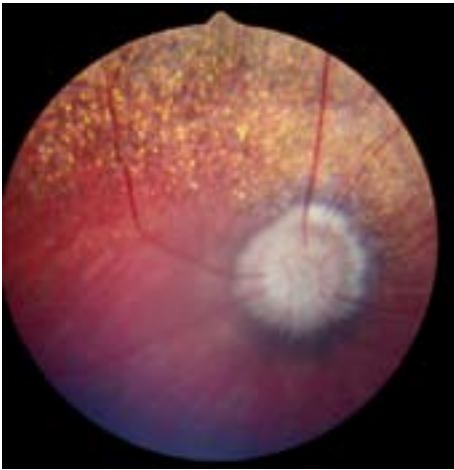
Generalised progressive retinal atrophy (GPRA) is an all-encompassing term for a number of different types of inherited retinal diseases in many breeds of dog (see table, below left). Two main types of GPRA affecting the photoreceptors are recognised in the UK: rod/cone dysplasia and rod/cone degeneration. The ophthalmoscopic signs and clinical progression are similar irrespective of type, with the exception of a late-onset form in which changes are first observed in the tapetal fundus just dorsal to its junction with the non-tapetal fundus. The age of onset of GPRA is variable, with dysplastic cases manifesting earlier in life than those in which the photoreceptors degenerate. Electroretinography is of value in early diagnosis, but is an exacting and difficult technique when used for this purpose.

Owners usually notice a loss of night vision (nyctalopia), especially when the dog is in unfamiliar surroundings. The disease progresses to produce a loss of vision under all lighting conditions. At this stage, signs include the presence of poor pupillary light reflexes and pupillo-dilation in ambient light. In time, secondary cataract formation is common. Ophthalmoscopic examination reveals a generalised, bilaterally symmetrical increase in tapetal reflectivity (a consequence of retinal atrophy). There is attenuation (narrowing) of the retinal vessels, especially the small peripapillary arterioles, which may become barely visible ('ghost vessels') or disappear completely. In dogs with a poorly developed tapetum or an atapetal fundus, attenuation of the retinal vessels may be the only obvious ophthalmoscopic sign of moderately advanced GPRA, and this can present a diagnostic challenge. Later in the course of the disease, the optic nerve head becomes paler due to atrophy of its capillaries and nerve fibres. The non-tapetal fundus also shows extensive areas of depigmentation as the condition progresses. The cataracts, which commonly develop late on in the disease process, often manifest initially as vacuolar or radial opacities in the posterior cortex, before progressing to become total.

NON-CONGENITAL INHERITED OCULAR DISEASE: GENERALISED PROGRESSIVE RETINAL ATROPHY

Certified – Schedule A
 Australian Cattle Dog
 Collie (Rough)
 Dachshund (Miniature Long-Haired)
 Finnish Lapphund
 Glen of Imaal Terrier
 Irish Setter
 Irish Wolfhound
 Lhasa Apso
 Miniature Schnauzer
 Norwegian Elkhound
 Poodle (Miniature)
 Poodle (Toy)
 Retriever (Chesapeake Bay)
 Retriever (Golden)
 Retriever (Labrador)
 Retriever (Nova Scotia Duck Tolling)
 Spaniel (American Cocker)
 Spaniel (Cocker)
 Spaniel (English Springer)
 Tibetan Spaniel
 Tibetan Terrier
 Welsh Corgi (Cardigan)

Under investigation – Schedule B
 Akita
 Dachshund (Miniature Smooth-Haired)
 Irish Setter
 Papillon
 Yorkshire Terrier



(left) Generalised progressive retinal atrophy in a Cocker Spaniel. Attenuation of the retinal vessels and pallor of the optic nerve head are the most obvious features as tapetal islets (a normal variant) do not produce the striking hyperreflectivity seen with a more extensive tapetum. Vision was seriously compromised in this dog. (middle) Generalised progressive retinal atrophy in a Miniature Poodle. Tapetal hyperreflectivity is obvious, and the optic nerve head is pale and the retinal vessels scarcely visible. The animal was almost totally blind. (right) Generalised progressive retinal atrophy in a Cocker Spaniel. An abnormal zone is apparent slightly dorsal to the optic nerve head. The zone appears dull or hyperreflective depending on the direction of the light source. The retinal vessels are marginally narrower than usual and the animal's vision was apparently unaffected

Significance

There is no cure for GPRA and the condition progresses to total blindness. In all the breeds listed under Schedule A, the disease is inherited as a simple autosomal recessive trait. DNA-based tests have helped to make breeding programmes more robust.

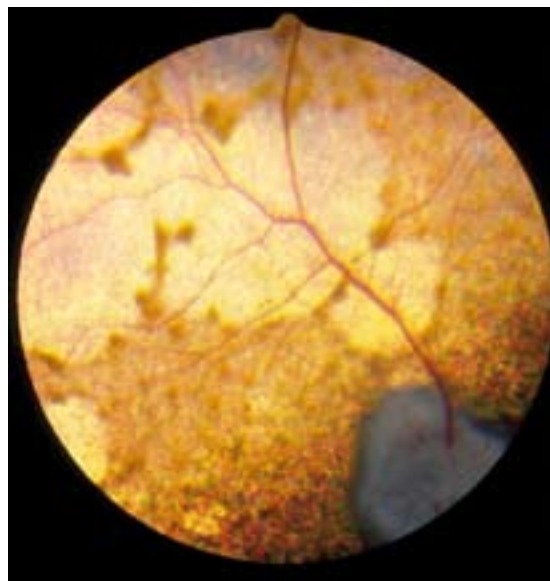
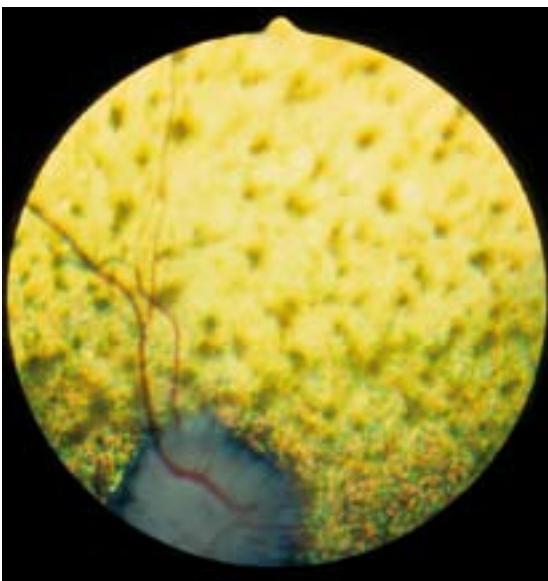
RETINAL PIGMENT EPITHELIAL DYSTROPHY

Retinal pigment epithelial dystrophy (RPED – also known as central progressive retinal atrophy) is a disease involving the cells of the retinal pigment epithelium. The relevant breeds under Schedules A and B are listed in the table, above right. Ophthalmoscopic signs may be detected on occasion in dogs aged just over 12 months, but it is more usual to make the diagnosis from about 18 months of age onwards. Electroretinography is not of value in early diagnosis.

NON-CONGENITAL INHERITED OCULAR DISEASE: RETINAL PIGMENT EPITHELIAL DYSTROPHY

Certified – Schedule A	Under investigation – Schedule B
Border Collie	Polish Lowland Sheepdog
Briard	
Collie (Rough)	
Collie (Smooth)	
Retriever (Golden)	
Retriever (Labrador)	
Shetland Sheepdog	
Spaniel (Cocker)	
Spaniel (English Springer)	
Welsh Corgi (Cardigan)	

The disease is caused by the inability of the retinal pigment epithelial cells to degrade spent photoreceptor metabolites, with the resultant accumulation of photoreceptor outer segment material (predominantly lipopigment) within the cytoplasm of the retinal pigment epithelial cells. Degeneration of the photoreceptors (rods and cones) occurs secondarily to the retinal pigment epithelial cell malfunction.



(left) Retinal pigment epithelial dystrophy in a Cocker Spaniel. At this relatively early stage, multiple focal accumulations of lipopigment are the most obvious feature, together with some vascular attenuation and a slightly pale optic nerve head. (right) Retinal pigment epithelial dystrophy in another Cocker Spaniel at a later stage of disease. The lipopigment has migrated to produce a more cobweb-like appearance

In dogs of working breeds, owners may notice an inability to work in bright light, while vision in dim light may be adequate until the disease is advanced. In pet dogs, suspect vision may not be noticed as early in the course of the disease. Affected dogs may exhibit a central visual defect initially, but the pupillary light response is often reasonable until the later stages of the disease. Complete blindness may take a considerable period to develop.

Ophthalmoscopic examination of early cases reveals the presence of multiple light brown foci in the tapetal fundus. These become more numerous and eventually coalesce into larger patches with hyperreflective areas between. In advanced cases, the lipopigment becomes less obvious as hyperreflectivity increases. The retinal blood vessels may become attenuated late in the disease, but the ophthalmoscopic appearance of the non-tapetal fundus and optic nerve head alters little. Both eyes are affected.

Significance

Unlike GPRA, RPED does not always result in total loss of vision, as peripheral vision may be maintained; secondary cataract formation is also unusual. However,

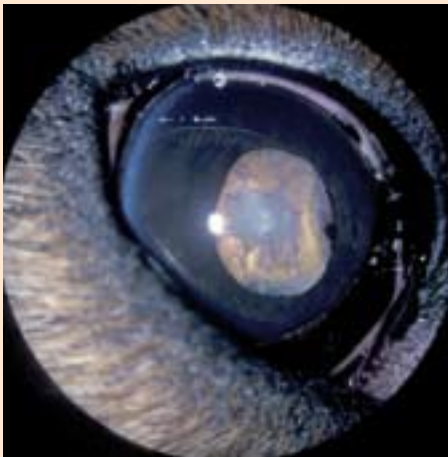
when the disease develops in a working dog, the effects are predictably serious. The inheritance of the disease appears complex, and environmental factors (eg, a poor quality diet) and levels of vitamin E may influence the phenotypic expression. Until more information is available, it is prudent to advise against breeding from affected dogs and their relatives. Significantly, and possibly as a consequence of a more balanced diet, the incidence of RPED in ISDS-registered dogs tested under the Eye Scheme is now less than 0.25 per cent.

DNA TESTING FOR INHERITED EYE DISEASES

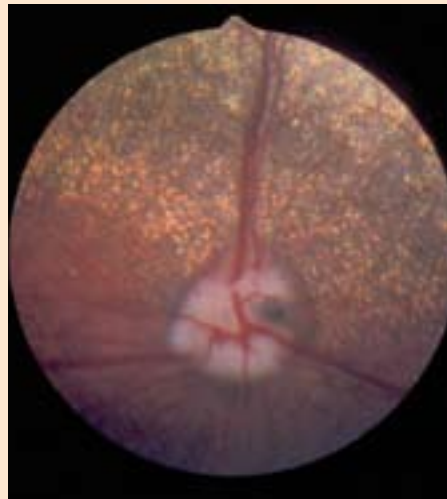
Most inherited eye diseases are caused by single gene mutations and, of these, the vast majority are recessive mutations (see table on page 14). This means that any individual dog will have one of three possible genetic compositions (genotypes) with regard to one of these single gene disorders:

- NORMAL, with two perfectly normal copies of the relevant gene;

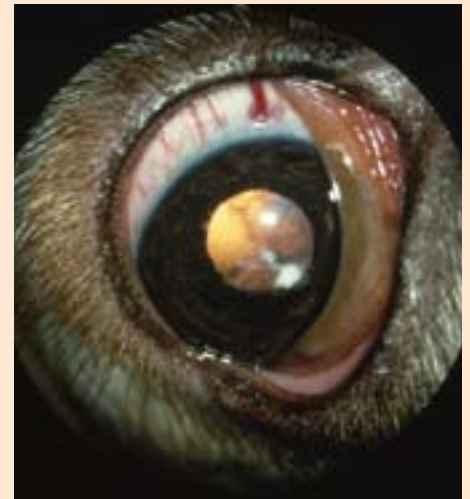Schedule B conditions



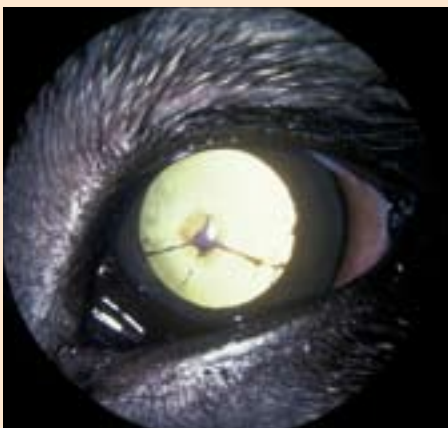
Congenital hereditary cataract and uveitis in a Golden Retriever. Note the darkly pigmented iris cyst in the pupillary aperture medially



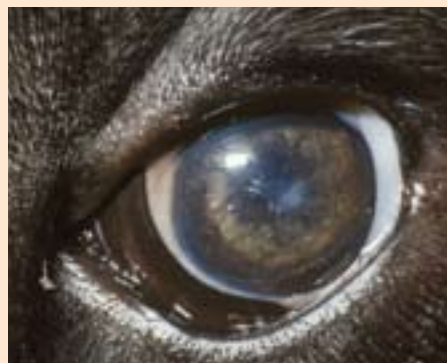Papillary coloboma



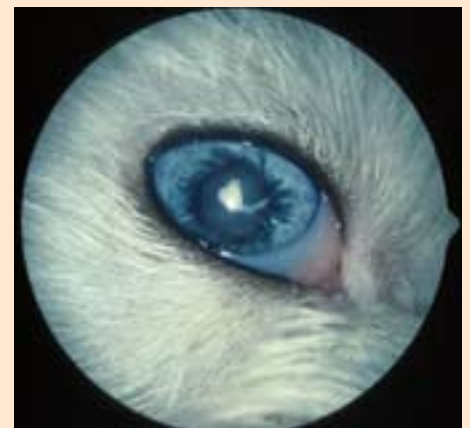Multiocular defects in a Cocker Spaniel. The eye is microphthalmic and a congenital cataract is present. Retinal dysplasia was an additional finding



Persistent pupillary membrane. Most of the remnants arise from the iris collarette and extend anteriorly to the cornea where a discrete opacity is present at the point of contact



Persistent pupillary membrane. Most of the remnants arise from the iris collarette and extend posteriorly to the lens. Note the associated pigment deposition on the anterior lens capsule



Multiocular defects in an Old English Sheepdog. The eye is microphthalmic and both a congenital cataract and persistent pupillary membrane remnants are present

■ **CARRIER**, with one normal copy of the relevant gene and one recessive, mutant copy;

■ **AFFECTED**, with two copies of the recessive mutation.

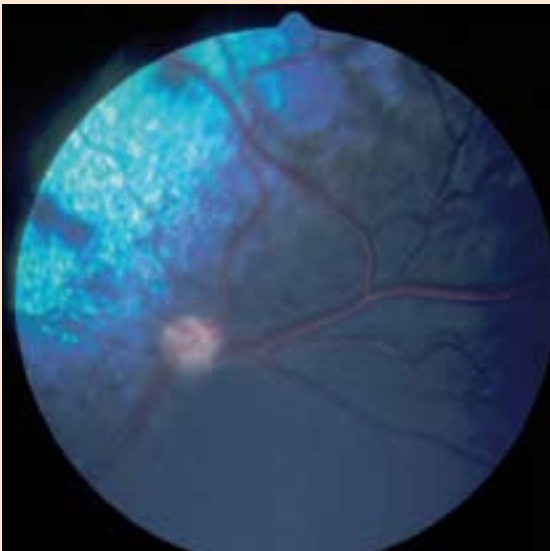
Dogs with the normal genotype are, of course, clinically (phenotypically) normal. Those with the carrier genotype are also clinically normal because the presence of the normal gene copy effectively silences the expression of the recessive mutant copy; therefore, only dogs with the affected genotypes are clinically affected and detected during the eye examination. Carriers can then be identified by pedigree analysis once an affected dog has been diagnosed; the clinically normal parents of an affected puppy are, by definition, carriers.

The past 10 years have seen remarkable progress in the understanding of canine molecular genetics, particularly since the publication of the canine genome sequence in 2004, which has greatly accelerated the identification of the mutations that cause some of these inherited ocular diseases. Once a particular mutation has been identified, it is usually a relatively simple task to develop a DNA test that can be used to determine an individual dog's genotype with respect to the disease. All that is needed for testing is a small amount of tis-

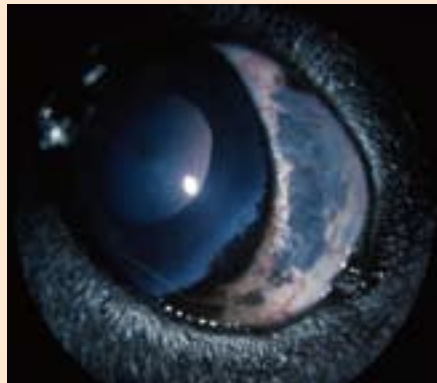
sue from the dog, from which its DNA can be extracted. Historically, blood samples were used as the source of DNA, but now buccal swabs can be used to detach cells from the inside of a dog's cheek and the DNA can be prepared and analysed from the cells harvested. These tests can detect all three genotypes an individual might possess in relation to an inherited ocular condition.

Given this progress, it is inevitable that both clinically based and DNA tests will become available for the same inherited eye condition and dual testing should be regarded as a complementary approach even if, on occasion, it leads to some apparent discrepancies. For example, a dog affected with a late-onset ocular condition could well be DNA tested as a young dog and identified as genetically affected, but could have clear eye examination results in the early part of its life because the eye examinations were undertaken before the onset of clinical signs.

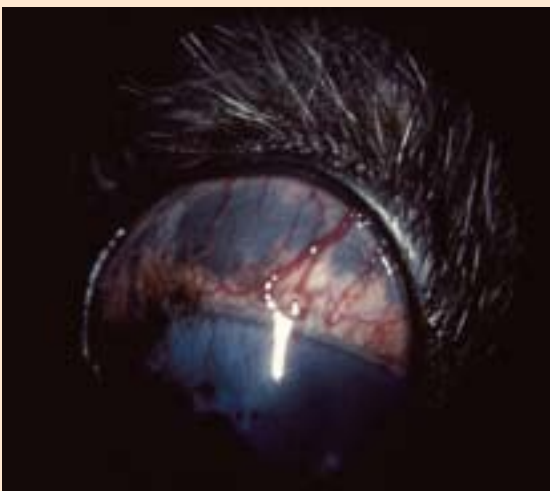
The 'variable expression' of some inherited eye diseases is complex and apparent discrepancies between clinical findings and genetic testing require further explanation. GPRA in the Miniature Long-Haired Dachshund is a good example: it presents clinically as an early-onset condition, with ophthalmoscopic diagnosis being pos-



Optic nerve hypoplasia in a Miniature Poodle



Abnormal pigment deposition in a Labrador Retriever



Abnormal pigment deposition in a Cairn Terrier

SCHEDULE B CONDITIONS UNDER INVESTIGATION (NOT LISTED ELSEWHERE)

- Australian Shepherd – coloboma
- Basenji – persistent pupillary membrane
- Basset Griffon Vendéen (Petit) – persistent pupillary membrane
- Bloodhound – multiocular defects
- Bullmastiff – persistent pupillary membrane
- Cairn Terrier – abnormal pigment deposition (diffuse ocular melanosis)
- Cavalier King Charles Spaniel – multiocular defects
- Collie (Rough) – multiocular defects
- Dachshund (Miniature Long-Haired) – optic nerve hypoplasia
- Dachshund (Miniature Wire-Haired) – persistent pupillary membrane
- Dobermann – multiocular defects
- Lancashire Heeler – persistent pupillary membrane
- Old English Sheepdog – multiocular defects
- Poodle (Miniature) – optic nerve hypoplasia
- Poodle (Standard) – multiocular defects
- Poodle (Toy) – optic nerve hypoplasia
- Retriever (Golden) – multiocular defects
- Retriever (Labrador) – abnormal pigment deposition (diffuse ocular melanosis)
- Rottweiler – multiocular defects and persistent pupillary membrane
- Siberian Husky – persistent pupillary membrane
- Spaniel (Cocker) – persistent pupillary membrane and multiocular defects
- West Highland White Terrier – persistent pupillary membrane and multiocular defects

DNA TESTS AVAILABLE FOR INHERITED EYE DISEASES	
Gene mutation	Breed
Generalised progressive retinal atrophy (GPRA)	
prcd	Australian Cattle Dog Australian Shepherd Chinese Crested Finnish Lapphund Hungarian Kuvasz Poodle (Miniature) Poodle (Toy) Portuguese Water Dog Retriever (Chesapeake Bay) Retriever (Labrador) Retriever (Nova Scotia Duck Tolling) Spaniel (American Cocker) Spaniel (Cocker) Spanish Water Dog Swedish Lapphund
rzd-1	Irish Setter Irish Red and White Setter
rzd -1a	Sloughi
rzd-3	Welsh Corgi (Cardigan)
cord-1	Dachshund (Miniature Long-Haired)
Dominant	Bullmastiff Mastiff
X-linked	Samoyed Siberian Husky
Type A	Miniature Schnauzer
Hereditary cataract	
HSF4	Boston Terrier (juvenile form) Staffordshire Bull Terrier
Collie eye anomaly	
CEA/CH	Australian Shepherd Border Collie Collie (Rough) Collie (Smooth) Lancashire Heeler Retriever (Nova Scotia Duck Tolling) Shetland Sheepdog Whippet
Congenital stationary night blindness	
csnb	Briard
Canine multifocal retinopathy	
cmr	Bullmastiff Coton De Tulear Dogue De Bordeaux Mastiff Pyrenean Mountain Dog
NB A number of the breeds for which a DNA test is available are not currently listed under Schedule A. For up-to-date information about DNA tests that are available, and the companies that offer them, contact: info@thekennelclub.org.uk	

sible at around six months of age. A DNA test specific for the mutation that causes progressive retinal atrophy in this breed is now available and extensive testing of the UK population of Miniature Long-Haired Dachshunds has identified a small number of dogs that are genetically affected as they are homozygous for the disease-causing mutation. However, they show no clinical signs of disease at nine or 10 years of age – thus, something in the rest of their genetic make-up may be delaying the onset of clinical signs. From a breeding selection standpoint, the genetic result must take precedence; the dogs are homozygous for the mutation and each of their offspring will inherit a mutant copy of the gene if the affected parent is used for breeding, irrespective of the clinical status of that parent.

Other potential complexities can be envisaged, especially when there may be different genetic causes of diseases with similar or identical clinical presentations. For example, a Miniature or Toy Poodle with classical clinical signs of late-onset GPRA might have a normal

Recording results

Eye examination results for all Schedule A conditions are passed to the Kennel Club, where the information is added to the relevant field on the dog's data on the Registration Database. A similar process is in place to deal with the results of DNA testing for inherited eye disease. Breed clubs that have one or more DNA tests are encouraged to establish an Official DNA Testing Scheme for the condition, whereby the DNA test results for individual dogs are sent directly to the Kennel Club and are added to the dog's registration data.

The addition of health screening results to the Kennel Club Registration Database triggers dissemination via a number of different routes. The result(s) will appear:

- On any new registration certificate issued for the dog;
- On the registration certificates of any of the dog's future progeny;
- In the Kennel Club Breed Records Supplement (BRS), a quarterly publication.

The Kennel Club also maintains lists of DNA test results for all Official DNA Testing Schemes on the health pages of its website (www.thekennelclub.org.uk).

DNA test result for prcd, a mutation that is known to cause progressive retinal atrophy in this breed. Under such circumstances it is important to appreciate that there could be at least two different types of inherited retinal atrophy in the breed.

SUMMARY

The BVA/KC/ISDS Eye Scheme offers a means of identifying the presence or absence of inherited eye disease in a variety of dog breeds. Ophthalmic examination and genetic laboratory testing, as necessary and where available, have removed much of the uncertainty from breeding programmes. There is no doubt that conscientious breeders wish to use sound stock with known freedom from inherited eye disease. All those involved in small animal practice can help to achieve this ideal by:

- Checking puppies' eyes when they come for their first vaccination;
- Informing pet owners about the Eye Scheme; and
- Ensuring that breeders recognise the need to utilise the Eye Scheme in any dog that is to be used for breeding.

Up-to-date information on the Eye Scheme, which includes the conditions certified in individual breeds (Schedule A) and under investigation (Schedule B) in a variety of breeds, is published annually in *The Veterinary Record*. Details of the procedure, including the appeals procedure, fees and panellists, can be found under the Canine Health Scheme section of the BVA website at www.bva.co.uk/canine_health_schemes/Eye_Scheme.aspx. Further details of the conditions referred to in this article, together with the relevant references, are contained in the Information for Panellists notes updated annually by the Chief Panellist, which can be found on the BVA website at www.bva.co.uk

BVA/KC/ISDS CHS Eye Scheme

Panel of Examiners January 1, 2009

Chief Panellist: Professor Sheila Crispin

England

Professor P. G. C. Bedford BVetMed PhD
DVOphthal FRCVS DipECVO
Royal Veterinary College, Hawkshead Lane,
Hatfield, Hertfordshire AL9 7TA
Telephone 01707 666333

Mr N. J. Burden BVSc CertVOphthal MRCVS
Hale Veterinary Group, 19 Langley Road,
Chippenham, Wiltshire SN15 1BS
Telephone 01249 653561

Mr J. Carter BVetMed DVOphthal MRCVS
Exeter Veterinary Ophthalmology Referrals,
c/o Raddenstiles Veterinary Surgeons,
Liverton Business Park, Salterton Road,
Exmouth, Devon EX8 2NR
Telephone 01395 264747

Mrs B. Cottrell MA VetMB CertVOphthal MRCVS
109 North End, Meldruth, Royston,
Hertfordshire SG8 6NX
Telephone 01763 262176

Professor S. M. Crispin MA VetMB BSc(Hons) PhD
DVA DVOphthal DipECVO FRCVS
Cold Harbour Farm, Underbarrow, Kendal,
Cumbria LA8 8HD
Telephone 020 7908 6380

Mr S. R. Ellis BVSc CertVOphthal MRCVS
Riverbank Veterinary Centre, 16/22 Watery Lane,
Preston, Lancashire PR2 2NN
Telephone 01772 726745

Mr P. J. Evans MA VetMB CertVOphthal MRCVS
Eye Veterinary Clinic, Marlbrook,
Leominster, Herefordshire HR6 0PH
Telephone 01568 616616

Miss H. J. Featherstone BVetMed DVOphthal
DipECVO MRCVS
Willows Referral Service, 78 Tanworth Lane,
Shirley, Solihull, West Midlands B90 4DF
Telephone 0121 745 1354

Mr K. J. Fraser BVMS CertVOphthal MRCVS
37 Caldecott Road, Abingdon, Oxfordshire OX14 5EZ
Telephone 01235 528177

Mr J. V. Goodyear BVMS CertVOphthal MRCVS
Glenthorne Veterinary Group, 25 Ashby Street,
Burton-on-Trent, Staffordshire DE15 0LG
Telephone 01283 519090

Dr D. J. Gould BSc(Hons) BVM&S PhD DVOphthal
DipECVO MRCVS
Davies Veterinary Specialists, Manor Farm Business
Park, Higham Gobion, Hertfordshire SG5 3HR
Telephone 01582 883950

Mr D. Habin BVMS DVOphthal MRCVS
Calder Vet Group, 159 Centre Huddersfield Road,
Mirfield, West Yorkshire WF14 9DQ
Telephone 01924 492155

Miss C. L. Heinrich DVOphthal DipECVO MRCVS
Willows Referral Service, 78 Tanworth Lane, Shirley,
Solihull, West Midlands B90 4DF
Telephone 0121 7451354

Mr M. P. C. Lawton BVetMed CertVOphthal CertLAS
CBiol MIBiol DZooMed(Reptilian) FRCVS
12 Fitzilian Avenue, Harold Wood,
Romford, Essex RM3 0QS
Telephone 01708 384444

Mr P. McPherson BVMS CertVOphthal MRCVS
Minster Veterinary Centre, Orchard Lodge,
Newark Road, Southwell,
Nottinghamshire NG25 0ES
Telephone 01636 812133

Mr I. K. Mason MA VetMB CertVOphthal MRCVS
Seadown Veterinary Hospital, Frost Lane,
Hythe, Hampshire SO45 3NG
Telephone 02380 842237

Mr J. R. B. Mould BA(Hons) BVSc DVOphthal MRCVS
Eye Veterinary Clinic, Marlbrook, Leominster,
Herefordshire HR6 0PH
Telephone 01568 616616

Mrs L. J. Newman BVMS CertVOphthal MRCVS
Pearl Veterinary Group, Longbow
Business Park, Harlescott, Shrewsbury,
Shropshire SY1 3AS
Telephone 01743 465554

Mr R. Pontefract BVMS CertVOphthal MRCVS
43 Empingham Road, Stamford,
Lincolnshire PE9 2RJ
Telephone 01780 764333

Mr P. W. Renwick MA VetMB DVOphthal MRCVS
Willows Referral Service, 78 Tanworth Lane,
Shirley, Solihull, West Midlands B90 4DF
Telephone 0121 745 1354

Ms K. Smith BVetMed CertVOphthal
DipECVO MRCVS
Davies Veterinary Specialists,
Manor Farm Business Park, Higham Gobion,
Hertfordshire SG5 3HR
Telephone 01582 883950

Ms S. Turner MA VetMB DVOphthal MRCVS
Mandeville Veterinary Hospital,
15 Mandeville Road, Northolt,
Middlesex UB5 5HD
Telephone 020 8845 5677

Mr C. G. B. Warren BA VetMB CertVOphthal MRCVS
Westmoor Veterinary Centre, Brook Lane,
Tavistock, Devon PL19 9BA
Telephone 01822 612561

Mr J. J. Yellowley BVSc CertVOphthal MRCVS
Rosemount Veterinary Hospital,
24 Old Woking Road, West Byfleet,
Surrey KT14 6HP
Telephone 01932 341058

Scotland

Mr M. G. Davidson BVMS CertVOphthal MRCVS
19 Hillhouse Road, Edinburgh EH4 3QP
Telephone 0131 332 0458

Mr A. T. McKenzie BVMS CertVOphthal MRCVS
McKenzie, Bryson & Marshall
21 Hill Street, Kilmarnock,
Ayrshire KA3 1HA
Telephone 01563 522701

Mr A. E. Wall BVMS CertVOphthal MSc MRCVS
Fish Vet Group, 22 Carsegate Road,
Inverness IV3 8EX
Telephone 01463 717774

Wales

Mr H. Cormie BVMS CertVOphthal MRCVS
Cormie Referrals, Tri-ar-Ddeg, 13 The Elms,
Oakdale, Blackwood, Gwent NP12 0EP
Telephone 07813 197222

Mrs G. E. Hubbard BVetMed CertVOphthal MRCVS
Cibyn Veterinary Clinic, Llanberis Road,
Caernarfon, Gwynedd LL55 2BD
Telephone 01286 673026

Northern Ireland

Mr I. Millar BVMS CertVOphthal MRCVS
Earlwood Veterinary Hospital,
193 Belmont Road, Belfast BT4 2AE
Telephone 028 9047 1361

Republic of Ireland

Dr T. D. Grimes BVetMed DVR DVOphthal
MRCVS DipECVO
Department of Small Animal Clinical Studies,
Faculty of Veterinary Medicine,
University College Dublin,
Belfield, Dublin 4, Ireland
Telephone 00 353 1716 6022

Appeals procedure

Any appeal against the results of an eye examination must be lodged in writing with the British Veterinary Association (BVA) **within 30 days** of the examination.

The owner may then take the dog, together with the certificate issued by the first panellist, for examination by another panellist. The second panellist will charge the normal fee. If the second panellist agrees with the first panellist, the appeal will be deemed to have failed and the second panellist will inform the BVA accordingly. In such an event, no further appeal is possible.

If the second panellist disagrees with the first panellist, the dog shall be referred to the Chief Panellist for further examination without additional fee to the owner. The decision of the Chief Panellist will be final and the Chief Panellist will advise the BVA of the result accordingly. (Owners may choose to see the Chief Panellist as the second panellist once an appeal has been lodged with the BVA. If so, the normal fee will be charged.)

The final result of any appeal must be received by the BVA **within 90 days** of the original examination; otherwise, the first result may be sent to the Kennel Club and/or the International Sheep Dog Society for publication.

Any appeal against the results of litter screening must be notified to the BVA and/or Chief Panellist as soon as possible so that suitable arrangements may be made for the whole litter to be re-examined **before** the puppies reach 12 weeks of age. No appeal may be granted unless all the puppies are re-examined on the same occasion and the puppies are less than 12 weeks of age.



Canine Health Schemes

7 Mansfield Street
London
W1G 9NQ

Tel: 020 7636 6541
Fax: 020 7908 6380
Email: chs@bva.co.uk



International Sheep Dog Society

Clifton House
4a Goldington Road
Bedford MK40 3NF

Tel: 01234 352672
Fax: 01234 348214
Email: office@isds.org.uk



The Kennel Club

1–5 Clarges Street
London
W1J 8AB

Telephone: 0870 606 6750
Fax: 020 7518 1058
www.thekennelclub.org.uk